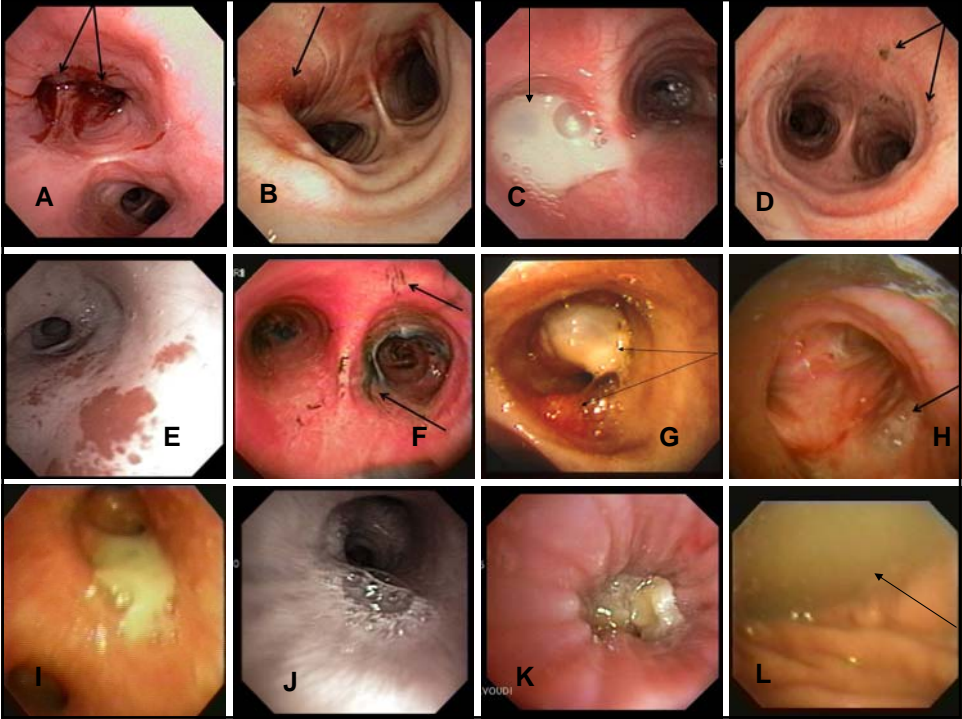
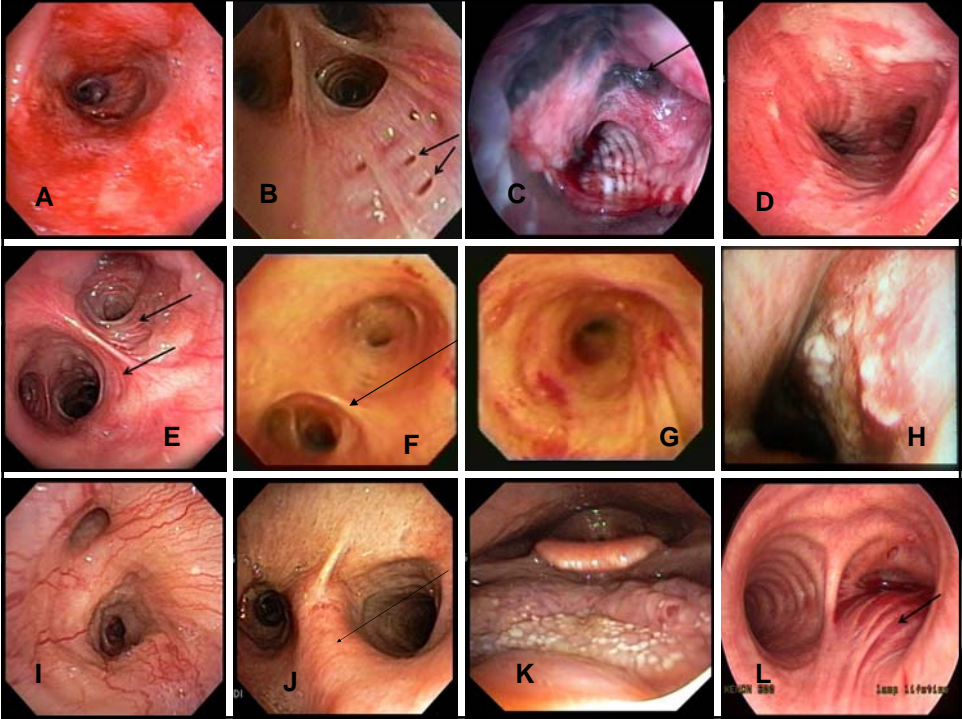


NAME _____



Match the photo (A-L) to the corresponding 10 secretion descriptions (Only one response per description)			
_____	_____	_____	_____
Sooty-burns	Bloody	Necrotic debris	Yellow purulent
_____	_____	_____	_____
White creamy	Normal clear	Tar-stained smoker's phlegm	Frothy covering TE fistula
_____	_____	NO RESPONSE	
Pink frothy edema	Scope trauma		

NAME _____



Match the photo (A-L) to the corresponding 10 mucosal descriptions (Only one response per description)			
_____	_____	_____	_____
Exophytic cancer	Necrotic tracheitis	Bronchial pits	Chronic bronchitis
_____	_____	_____	_____
Hypervascularity	Tumor infiltrated carina	Extrinsic compression	Anthracosis
_____	_____	NO RESPONSE	
Oral candidiasis	Acute bronchitis		