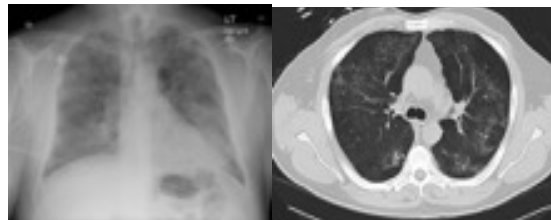




Clinical Case 1: Flexible Bronchoscopy with Bronchioloalveolar lavage for diagnosis

AA is a 64 year old retired physician has been admitted to your hospital with change in mental status, a recent history of chemotherapy for lymphoma, fever, and diffuse, bilateral pulmonary infiltrates. He smoked one pack per day for twenty years but quit 15 years ago. He is married (his wife is a nurse), and has two children, one of whom is a medical doctor who lives nearby. The patient's physical examination shows lower extremity edema, an erythematous rash on his back, decreased breath sounds bilaterally and occasional right sided expiratory wheezing. His neurologic examination is normal. He is oriented, but not always alert. Oxygen saturation is 90% on 3 liters by nasal canula, blood pressure is elevated heart rate is 110 beats per minute. Arterial blood gases show normal pCO₂ and pH. His medications include aspirin 325 mg, clodipogrel (Plavix), which was stopped three days ago because of a lumbar puncture which was negative), prednisone, and Atorvastin calcium (Lipitor). His past medical history also includes hypertension, a right coronary artery stent placed six months ago, migraine headaches, and uneventful cholecystectomy five years ago.

The chest radiograph reveals diffuse bilateral infiltrates with a ground glass pattern in the right upper and left lower lobes, as well as a widened carina. A computer tomography scan with contrast confirms these findings, and also shows enlarged subcarinal adenopathy. The oncology consultant is concerned about recurrent or persistent lymphoma, but cannot exclude a new neoplasm (the subcarinal adenopathy is a new finding). The infectious disease consultant is concerned about a pulmonary infection, especially because the patient's recent blood work shows prolonged neutropenia secondary to chemotherapy and normal platelet counts.



After addressing items of the four boxes, briefly respond to the following questions:

1. What are the arguments for and against performing transbronchial lung biopsy in this scenario?
2. What are the arguments for and against performing transcarinal needle aspiration in this scenario?
3. What medications warrant extra precautions to prevent bronchoscopy-related bleeding?
4. What would you do if physicians requesting the procedure insist on a biopsy even if you believe it is not immediately warranted?
5. What procedure(s) would you perform?